

NO 20 SORBACT[®] CLINICAL CASE

Pressure ulcer

WOUND TYPE

Pressure ulcer

PRODUCT

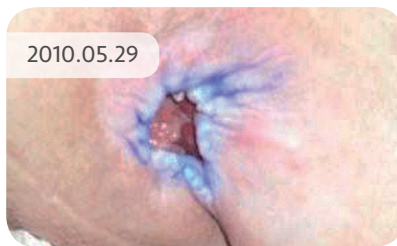
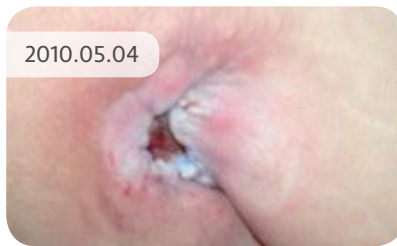
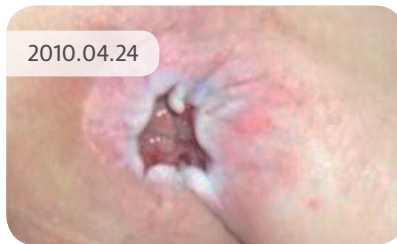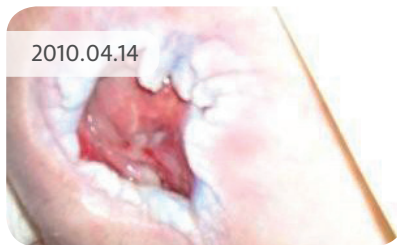Sorbact[®] Compress

COUNTRY/LOCATION

DK - Ringkøbing-Skjern Municipality

TREATMENT PERIOD

14 April – 30 May, 2010



THE PATIENT

A 49-year-old woman with multiple sclerosis. Incurred a pressure ulcer to the sacrum. It has been a long course of treatment and the patient is being monitored by the wound clinic in Ringkøbing Hospital. She has a pressure relieving mattress and a pillow in the wheelchair.

THE TREATMENT

The patient agreed to use the Sorbact[®] Compress for a five week evaluation period. Initial ulcer size was 4 x 6cm.

WOUND CARE

Wound care is performed by the home health care nurse or healthcare assistant on a daily basis.

The wound was flushed using water with a 60 ml sprayer and a flushing shield.

Wound edges dabbed with Metylrosalin.

Sorbact[®] Compress was applied to the wound.

Alginate.

Foam dressing with edges.

14 April, 2010 The wound now measured 3 x 4 cm and 1cm in depth. The wound edges were thickened with the peri-wound skin erythematous. The wound was malodorous and heavily exuding.

24 April, 2010 The wound measured 3 x 3 cm and 0.7 cm in depth. General improvement noted and management continued.

4 May, 2010 General improvement noted again and management continued.

30 May, 2010 The wound finally measured 2 x 2.5 cm and 0.5 cm in depth. Wound edges settled with minimal odourless exudate noted.