

# NO 9 SORBACT® CLINICAL CASE

Pressure ulcer of the sacrum

## WOUND TYPE

Pressure ulcer

## PRODUCT

Sorbact® Gel Dressing  
and Sorbact® Compress

## COUNTRY/LOCATION

DK - Fredensborg Municipality

## TREATMENT PERIOD

6 November, 2009 – 6 January, 2010

## THE PATIENT

66 year old female sustained a pressure ulcer over the sacrum. Medical co-morbidities include Multiple Sclerosis and insulin dependent diabetes mellitus.

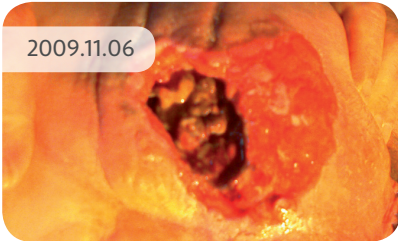
## THE TREATMENT

**6 November, 2009** Wound management commenced with Sorbact® Gel Dressing and Sorbact® Compress to fill in the cavity. A superabsorbent dressing was placed on top to manage the exudate from the wound. The wound was described as uneven with the depth varying from superficial to up to 3cm in depth.

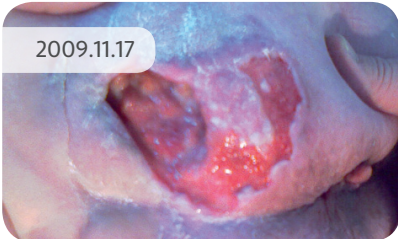**6 January, 2010** Wound improvement quite noticeable. Treatment with Sorbact® Gel Dressing and Sorbact® Compress was continued.

**2 February, 2010** At this stage a small wound remained. Management continued with Sorbact® Gel to ensure complete wound healing from the base.

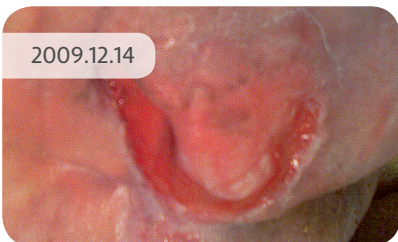
2009.11.06



2009.11.17



2009.12.14



2010.01.06

