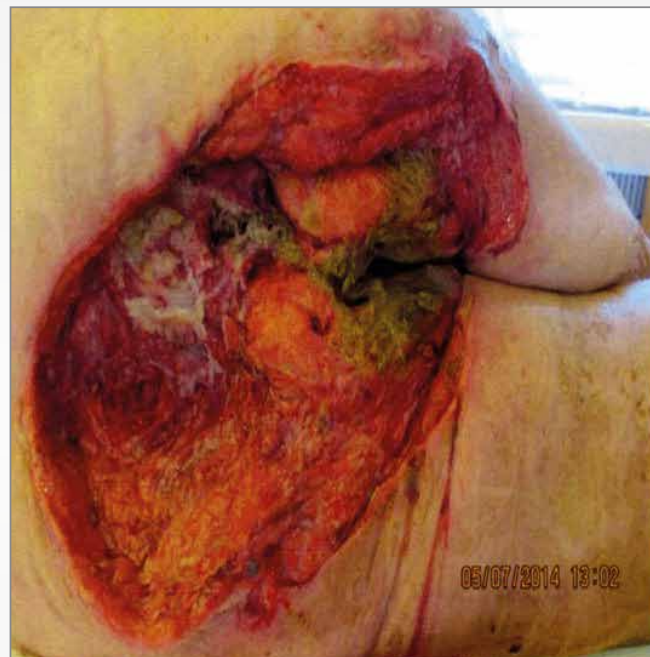


# Management of an infected decubitus ulcer using a bacteria and fungi binding dressing\*

Lisa Petersen and Vibeke Orskov. Wound Care, Endocrinology Hvidovre Hospital, Denmark. lisa.anja.petersen@regionh.dk

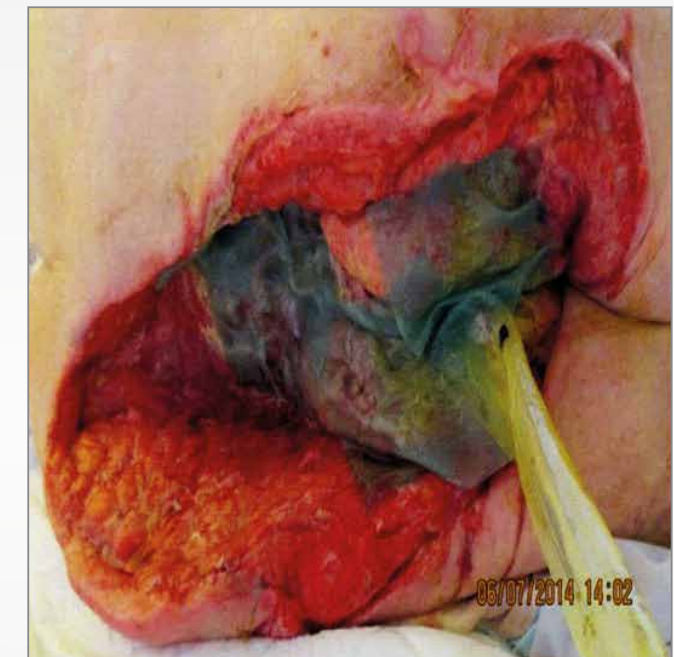
## Background

- 69 yr old female
- Fell from wheelchair, helpless for 2 days
- Rhabdomyolysis, severe systemic infection. 40x30cm decubitus ulcer
- Infected, highly exuding malodorous wound



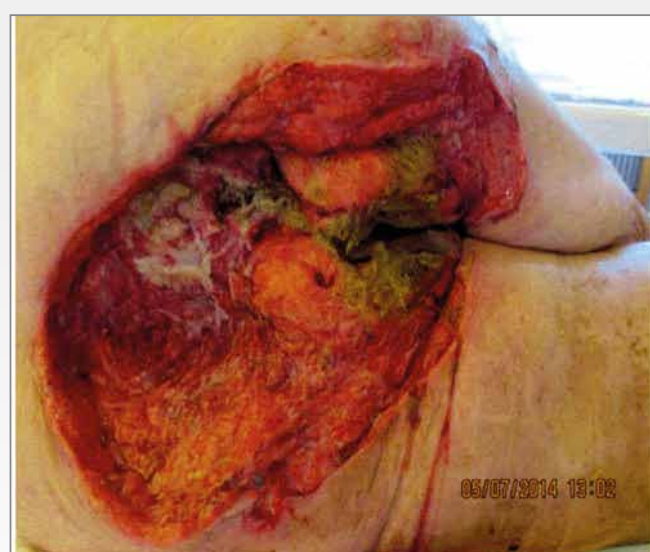
## Management

- Surgical Debridement
- IV Tazocin and metronidazole
- Once medically stable, 9 weeks wound management followed
- Bacteria and fungi binding dressing\* applied

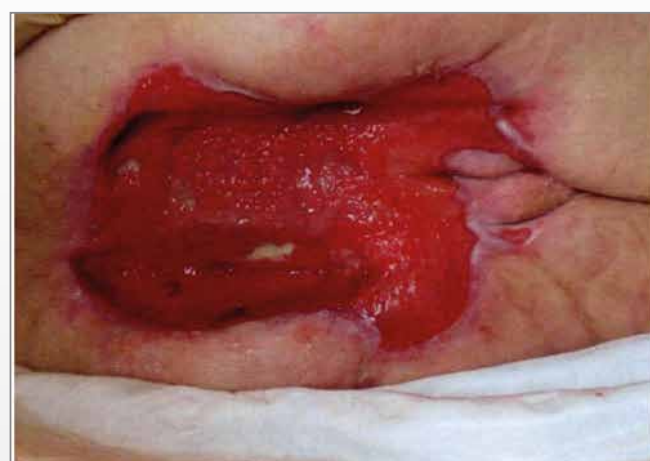

## Results

- 9 weeks of care
- Holistic approach to wound healing.
- Wound dressing selection management prevented infection recurrence.
- Bacteria binding gel dressing safe and easy to use.



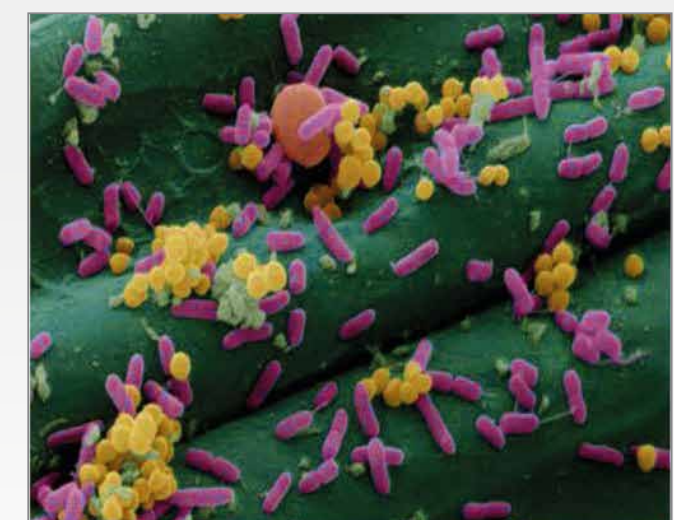40 x 30 cm



14 x 11 cm

## Discussion

- Bacteria and fungi bind to dressing\*
- Prevents infection.
- No chemicals.
- Decrease of wound bioburden promotes healing.



Wound bacteria and fungi bind to the dressing\*.

\* Sorbact Gel Dressing - ABIGO Medical, SWEDEN

